

ORIGINAL ARTICLE

Safety and efficacy of low-fluence, high-repetition rate versus high-fluence, low-repetition rate 810-nm diode laser for permanent hair removal – A split-face comparison study

GANESH S. PAI¹, PAVRITHA S. BHAT¹, HEMA MALLYA¹ & MICHAEL GOLD^{2,3}

¹Derma-Care Skin & Cosmetology Centre, Mangalore, Karnataka, India, ²Gold Skin Care Center, Tennessee Clinical Research Center, Nashville, TN, USA, and ³Vanderbilt University School of Medicine and Vanderbilt University School of Nursing, Nashville, TN, USA

Abstract

Background: This study was designed to evaluate the hypothesis that low-level fluences done repetitively on a hair follicle will produce permanent hair removal with less discomfort and fewer side effects than a single high-fluence pulse. **Objective:** To compare the safety and efficacy of a low-fluence, high-repetition rate versus a high-fluence, low-repetition rate 810-nm diode laser for permanent hair reduction in patients with facial hirsutism. **Methods:** Forty-two female patients with confirmed polycystic ovaries by ultrasonography with facial hirsutism were subjected to the low-fluence, high-repetition Soprano[®] XL laser in SHR mode and the LightSheer[™] laser on each side of the face using preset parameters once a month for six sessions. Hair counts were done at the end of the sixth session using a 'Hi Quality Hair Analysis Program System' and the pain score was recorded by a visual analog scale. **Results:** The overall median reduction of hair was 90.5% with the Soprano XL and 85% with the LightSheer, with a standard deviation of 7 and 8.5 respectively. **Discussion:** This new technology, with low fluence and high repetition, showed a statistically insignificant increase in hair reduction compared to the LightSheer, but did show a significant reduction in hair thickness and a low pain score.

Key Words: fluence, laser, LightSheer, Soprano XL

Introduction

Laser hair removal has become an accepted form of long-term hair reduction and is now one of the most common dermatologic procedures (1). The absorption of the laser light by a specific chromophore, regardless of the active medium, transforms the energy into heat, with the rate and extent of heating determined by the power density (power output/effective spot size) and the duration of exposure. The resulting thermal damage can lead to denaturation or irreversible coagulation of proteins or, if the temperature is more than 100°C, vaporization of tissue (2).

In recent years, a variety of lasers and pulsed light sources have been introduced for hair removal (3). The first involved a Q-switched Nd:YAG laser (1064 nm) used in conjunction with a topical carbon-mineral oil suspension, the carbon acting as a chromophore. However, this system showed minimal effectiveness for long-term hair removal (4,5). More

positive results have been achieved with the long-pulsed ruby laser (694 nm) (6,7), the long-pulsed alexandrite laser (755 nm) (8), the diode laser (800 nm) (9,10), and a variety of filtered, flashlamp pulsed-dye lasers (11,12), all of which use melanin as the chromophore for selective photothermolysis. Selective thermal damage of pigmented target structures occurs when sufficient fluence at a given wavelength, preferentially absorbed by the target, is delivered during a time approximately equal to or less than the thermal relaxation time of the target (13).

The present study compares the efficacy, safety and treatment speed of a new low-fluence, rapid-pulse, with multiple passes, 810-nm diode laser with a traditional high-powered, single-pass, 810-nm diode laser system. The approach of using low fluencies with repetitive millisecond pulses to achieve heat stacking in the hair bulb and bulge represents a paradigm shift in laser hair removal.

Materials and methods

This was an open-label, single-centre, prospective clinical study. A total of 42 female patients above the age of 18 years with facial hirsutism with Fitzpatrick skin types IV and V with polycystic ovaries confirmed by ultrasonography were enrolled in the study. The following patients were excluded from the study: patients with obvious skin disease or a history of chronic skin disease other than moderate facial acne vulgaris; keloidal or hypertrophic scar tendency; skin types I, II, III, and VI; severe photosensitivity; and pregnant patients. Prior to treatment an informed written consent was signed by each patient.

Using the manufacturer-recommended methods and settings, one side of the face of each patient (randomly determined) was treated with the Soprano® XL (Alma Lasers Ltd, Caesarea, Israel) in SHR mode using a technique of maintaining the handpiece in constant motion, with a fluence up to 10 J/cm², 10 Hz, and a 20-ms pulse duration as recommended by the manufacturers.

We achieved our desired results with fluences which ranged from 5 to 8 J/cm². The area to be treated was first shaved and a cool ultrasound gel applied.

The other side of the face was treated with the LightSheer™ (Lumenis, Inc., Santa Clara, CA, USA) using a conventional single-pass fluence to tolerance (25–35 J/cm²), 2 Hz, and a 30-ms pulse duration (which was the pulse width found safest in our patient population based on past experiences on skin types IV and V).

The subjects were treated six times at intervals of 4–6 weeks with each device to permit hair regrowth and mimic real-life laser hair removal.

Baseline hair density and final hair counts after the sixth session were made within a predetermined square-shaped area (2 × 2 cm² area from the tip of the ear lobule to the jaw line) by using the hair analysis system SIF-1 for accuracy.

Pain during the treatment was measured subjectively by patients on a 0–10 visual analog scale (0 = no pain, 10 = unbearable pain) and recorded by evaluation for each side of the face after each treatment session.

Results

A total of 42 female patients above the age of 18 years with facial hirsutism completed the study. Nine additional patients were enrolled but did not finish the protocol and were excluded from the results. All the data were analyzed using appropriate statistical tests at the end of six sessions of treatment, which included the paired *t*-test. Statistical significance was considered to be $p < 0.05$.

Based on hair density recorded at the beginning and the end of the treatment session, we found that the overall median reduction of hair was 90.5% with

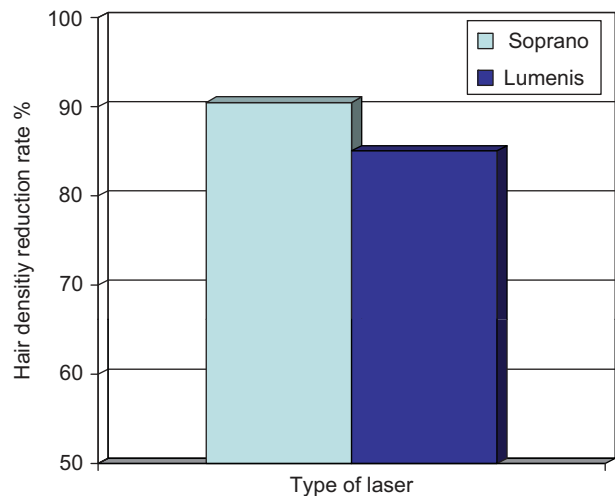


Figure 1. Graph comparing the overall median hair removal percentages for Soprano XL (90.5%) and LightSheer (85%).

the Soprano XL in SHR mode and 85% with the LightSheer, with a standard deviation of 7 and 8.5 respectively (Figure 1). Comparing the hair removal percentages between these two lasers using the paired *t*-test, we found that these differences were not statistically significant ($p < 0.063$).

However, on analyzing the hair width (mm) (measured using a hair analysis system), a much more striking observation was noted as the median hair width was reduced to 0.02 mm with the Soprano XL and 0.05 mm with the LightSheer (Figure 2). This was statistically different with a *p*-value of < 0.0005 .

We observed that the median pain scores of the Soprano XL and the LightSheer were 2 and 6, respectively (Figure 3), as measured on a 0–10 visual analog scale (0 = no pain, 10 = unbearable pain) over the six treatment sessions. The difference between median overall pain scores was 4, which is statistically very significant ($p < 0.0005$).

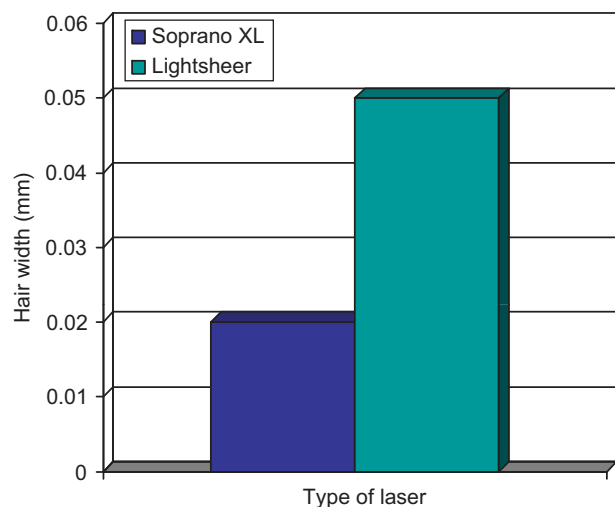


Figure 2. Graph comparing the overall median hair width reduction for Soprano XL (0.02 mm) and LightSheer (0.05 mm).

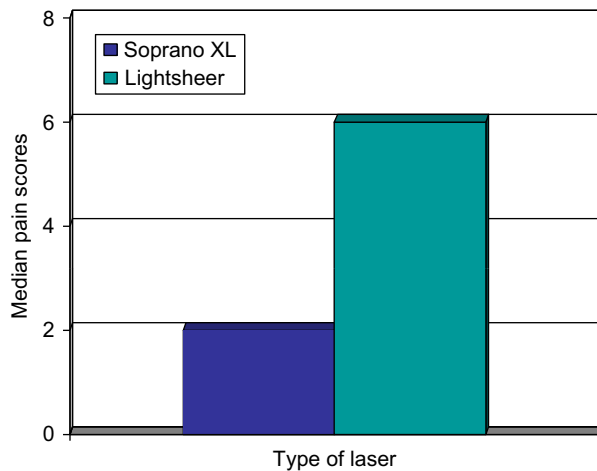


Figure 3. Graph comparing the overall median pain scores for Soprano XL (2) and LightSheer (6).

There were no adverse events noted during the course of the study.

Discussion

High-fluence diode lasers with contact cooling have emerged as the gold standard to remove unwanted hair. However, laser hair removal can be painful, and can result in hypopigmentation or post-inflammatory hyperpigmentation, especially in dark skin tones (14,15). Lowering the energy should result in less pain and fewer potential adverse events, but this could theoretically affect the efficacy of the therapy. This study showed that results using low-energy, high-repetition diode laser pulses with the Soprano XL in SHR mode are comparable in hair reduction to the traditional high-fluence, single-pass technique using the LightSheer laser. The approach of using low fluences with repetitive millisecond pulses to achieve heat stacking in the hair bulb and bulge represents a paradigm shift in laser hair removal methodology. With the Soprano XL system, the epidermal protection is achieved by the handpiece's sapphire contact cooling system. The system does not target melanin as the principle target chromophore. Instead, the Soprano XL focuses on raising the temperature of the sub-dermal layer of the skin progressively to at least to 45°C, and to less than the thermal destruction temperature of the hair follicle without heating the epidermis of the skin region. Although the fluence of each pulse delivered to the skin is relatively low, the rapidly delivered pulses effectively heat the dermis.

The Soprano XL in SHR mode has several advantages over traditional high-fluence treatments, including less pain and theoretically a lower incidence of adverse effects, especially in dark-skinned individuals.

With this technique, the laser handpiece never remains stationary in one spot, but is always moving in the treatment area – similar to what we would do while ironing. Hence, the skin is never subjected to a single diode laser pulse greater than 10 J/cm². Since this is below the threshold of burning, the incidence of adverse effects is lower, as well as the sensation of discomfort, which is directly related to fluence. We had a median pain score of 2/10 for the Soprano XL, versus 6/10 for the LightSheer. This was statistically significant. Further, this new technology with low fluence and high repetition showed a statistically insignificant increase in hair reduction compared to the LightSheer, yet it did show a significant reduction of hair thickness when the remaining hairs were measured. This was subjectively felt by the patients in the study and confirmed by measurement of the hair shaft. The reduced level of pain with the low-frequency modality laser increased patient compliance with the procedure. This can be better explained by the fact that all patients who underwent laser hair removal with the Soprano XL were calm and relaxed during the procedure; however, with the LightSheer diode patients moved, by reflex, away from the handpiece owing to pain and physical discomfort. Patients who subjectively wished to treat other parts of the body opted for this less painful laser. Further, all 42 patients who were enrolled completed the study.

In a similar study by Braun (14), similar observations for pain score and hair reduction were seen. A significant difference was that our study was conducted on androgen-dependent facial hair in contrast to leg hairs in the Braun study. We were also able to quantify hair loss and the thickness of the remaining hairs with the help of a hair scanner device.

A histopathology study was not done as it was not considered relevant to the scope of this study.

Conclusion

We concluded that low-level fluencies performed repetitively on a hair follicle will produce permanent hair reduction with less discomfort and fewer side effects than a single, high-fluence pass. Both devices produced hair reduction counts in excess of 80% 6 months following the first treatment; however, treatment with the Soprano XL produced a more significant reduction in hair thickness in subsequent sessions as compared with the LightSheer. Overall, the concept of this new technology has translated into greater acceptance by patients in terms of finer recalcitrant hairs and less pain during the procedure.

Conflicts of interest

Dr Gold speaks on behalf of Alma Lasers and Lumenis.

Funding

No financial support to disclose.

References

1. Hamzavi I, Tan E, Shapico J, Lui H. A randomized bilateral vehicle controlled study of eflornithine cream combined with laser treatment alone for facial hirsutism in women. *J Am Acad Dermatol.* 2007;45:52–56.
2. Dover JS, Arndt KS. *Illustrated cutaneous laser surgery: A practitioner's guide.* Norwalk, CT: Appleton & Lange; 1990. p. 45–48.
3. Olsen EA. Methods of hair removal. *J Am Acad Dermatol.* 1999;40:143–155.
4. Goldberg DJ. Various mechanisms of hair removal. *Cosmet Dermatol.* 1997;10:36–38.
5. Nanni CA, Alster TS. Optimizing treatment parameters for hair removal using a topical carbon-based solution and 1064 nm Q-switched neodymium:YAG laser energy. *Arch Dermatol.* 1997;133:1546–1549.
6. Grossman MC, Dierickx C, Farinelli W, Flotte T, Anderson RR. Damage to hair follicles by normal-mode ruby laser pulses. *J Am Acad Dermatol.* 1996;35:889–894.
7. Dierickx CC, Grossman MC, Farinelli WA, Anderson RR. Permanent hair removal by normal-mode ruby laser. *Arch Dermatol.* 1998;134:837–842.
8. Finkel B, Eliezri YD, Waldman A, Slatkine M. Pulsed alexandrite laser technology for non-invasive hair removal. *J Clin Laser Med Surg.* 1997;15:225–229.
9. Dierickx CC, Grossman MC, Farinelli WA, Anderson RR. Hair removal by a pulsed, infrared laser system. *Lasers Surg Med.* 1998;(suppl 10):198.
10. Grossman MC, Dierickx CC, Quintana A, Geronemus R, Anderson RR. Removal of excess body hair with an 800 nm pulsed diode laser. *Lasers Surg Med.* 1998;(suppl 10):201.
11. Smith SR, Goldman MP, Fitzpatrick RE. Long term results of hair photo-epilation. *Lasers Surg Med.* 1998;(suppl 10):205.
12. Weiss RA, Weiss MA, Marwaha S, Harrington AC. Hair removal with a non-coherent filtered flashlamp intense pulsed light source. *Lasers Surg Med.* 1999;24:128–132.
13. Anderson RR, Parrish JA. Selective photothermolysis: Precise microsurgery by selective absorption of pulsed radiation. *Science.* 1983;220:524–527.
14. Braun M. Permanent laser hair removal with low fluence high repetition rate versus high fluence low repetition rate 810 nm diode laser—A split leg comparison study. *J Drugs Dermatol.* 2009;8:14–17.
15. Patil UA, Dhama LD. Overview of lasers. *Indian J Plast Surg.* 2008;41:101–113.