

Efficacy and safety of fractional Q-switched 1064-nm neodymium-doped yttrium aluminum garnet laser in the treatment of melasma in Chinese patients

Baishuang Yue¹ · Qianli Yang¹ · Jinhua Xu¹ · Zhong Lu¹

Received: 15 March 2016 / Accepted: 13 July 2016
© Springer-Verlag London 2016

Abstract Melasma is an acquired disorder of symmetrical hyperpigmentation commonly seen in patients with Fitzpatrick skin types III and IV. Various novel therapeutic modalities have emerged to treat melasma. The large-spot low-fluence QS Nd:YAG laser has been widely used in Asia; however, the modality needs to be optimized because of the high recurrence rate. The objective of this study is to explore the clinical efficacy and safety of fractional-mode (Pixel) Q-switched neodymium-doped yttrium aluminum garnet (Nd:YAG) 1064-nm laser for treatment of melasma in Chinese patients. Twenty-seven patients were enrolled and completed all the treatment sessions and the 12-week follow-up. All were treated using the fractional-mode Pixel QS Nd:YAG (1064 nm) laser for eight sessions at a 2–3-week interval. Clinical photographs were taken using the Visia skin analysis imaging system. Two blinded assessors evaluated melasma area and severity index (MASI) scores before and 4 weeks after the final session. Melanin index (MI) and erythema index (EI) was measured before each treatment visit and after the final treatment. The degree of pigmentation and erythema was assessed using a tristimulus color analyzer. Physicians' global assessment (PGA) and patients' self-assessment were taken as the subjective assessments. Wilcoxon signed-rank test was performed to evaluate clinical response. Recurrence rate were also evaluated. Mean MASI scores decreased from 12.84 ± 6.89 to 7.29 ± 4.15 after treatment ($p = 0.000$). Seventy percent of patients got moderate to

good improvements after all the treatment. Mean MI decreased significantly from 56.52 ± 23.35 to 32.75 ± 12.91 ($p = 0.000$). *L* value increased from 59.21 ± 2.22 before treatment to 61.60 ± 2.40 ($p = 0.000$) after therapy. The mean score of PGA was 3.76 ± 0.71 , indicating a “moderate” clearance of the lesion. In patients' self-evaluations, 70 % of the patients rated the result as “good” to “remarkable.” Partial recurrence was seen in 40 % patients at the 3-month follow-up. No severe adverse events were observed during the study, and the treatment was well tolerated. The fractional mode (Pixel) QS Nd:YAG 1064-nm laser is an effective and safe treatment for melasma. The recurrence rate was relatively lower than that reported in studies treating with large-spot low-fluence QS Nd:YAG laser.

Keywords 1064-nm Nd:YAG laser · Fractional laser · Melasma

Introduction

Melasma is an acquired disorder of symmetrical hyperpigmentation appearing as light brown to dark, muddy brown macules and patches on the face, especially the forehead, malar areas, and chin and commonly seen in patients with Fitzpatrick skin types III and IV [1]. While the exact etiology and pathogenesis for melasma remains unclear, it was well accepted that risk factors include genetic predisposition, exposure to ultraviolet light, pregnancy, estrogen (i.e., oral contraceptives and hormone replacement therapy) [1, 2], and thyroid dysfunction [3].

The treatment of melasma is a challenge and can be difficult for its refractory and recurrent nature. A variety of therapeutic approaches include topical formulations, chemical peels, oral medication, lasers, and light sources [4, 5]. Based on the theory of selective photothermolysis, Q-switched (QS) lasers have proven effective for a large number of skin

Baishuang Yue and Qianli Yang contributed equally to this work.

✉ Zhong Lu
luzhong0307@sina.com

¹ Department of Dermatology, Huashan Hospital, Fudan University, No. 12 Wulumuqi Road, Jing'an District, Shanghai 200040, China

pigmentary disorders including melasma. Low-energy, large-spot Q-switched Nd:YAG laser (1064 nm) therapy has been widely applied in melasma with certain degrees of success. Recent studies on its mechanism of action suggested that melanin was selectively destroyed while melanocytes were left intact, which was described as subcellular photothermolysis [6, 7]. However, its long-term efficacy has to be improved; since the recurrence rate is usually high [8], rebound hyperpigmentation and hypopigmentation were common side effects [8–13]. It may be caused by the excessive cumulative laser energy of multiple treatments.

Fractional-mode has been developed in recent years which combined fractional mode with QS Nd:YAG laser (1064 nm). Considering that the additional mode may prevent excessive cumulative laser energy, this prospective study was conducted to explore the clinical efficacy and safety of fractional-mode (Pixel) Nd:YAG laser (Harmony XL, Alma Lasers Ltd. Caesarea, Israel) in treating melasma in Chinese patients in the hope of treating melasma with high efficacy and low recurrence rate.

Materials and methods

Patients

Thirty patients with mild to severe melasma with skin types III or IV were recruited at the general out-patient clinic of the Department of Dermatology in Huashan Hospital.

Exclusion criteria were pregnancy, lactating or on any hormonal therapy, use of topical bleaching agents (such as hydroquinone, tretinoin, kojic acid, azelaic acid) within 6 months prior to study, use of topical corticosteroids within 1 month prior to study, laser or intense pulsed light therapy in the treatment regions within 3 months prior to study, photo-sensitizing medication within 3 months prior to study, excessive photosensitivity to normal sunlight, inflammatory disease of the skin, connective tissue diseases, and thyroid dysfunction.

Written informed consent was obtained from all patients prior to enrollment in accordance with the “Helsinki declaration.” This clinical study was approved by the Ethics Committee of Huashan Hospital.

Treatment protocols

Patients was treated with a Fractional Q-Switched Nd:YAG laser (Pixel Nd:YAG laser handpiece, Harmony XL, Alma Lasers Ltd. Caesarea, Israel) at a wavelength of 1064 nm, a spot size of 8.5*8.5 mm containing 25 dots. The diameter of each dot was 1.25 mm, and the area of coverage was 42.4 %.

Eight sessions of treatment at 2–3-week interval were performed on each patient. The laser parameters used were 800 to 1100 m J/P (approximately 2.6–3.6 J/cm²)

of fluence and repeated frequency of 2 Hz. The lesions were scanned three passes with slight erythema as the proper endpoint. No other kinds of treatment were administered. Sunscreen with a sun protection factor greater than 30 and PA+++ was required daily on the whole face during the entire study. To ensure consistency, all laser treatments were performed by the same therapist.

Assessment

Clinical photographs were taken using the Visia skin analysis imaging system (Canfield Scientific co, Fairfield, NJ) and a digital camera (Canon EOS 400D, Tokyo, Japan) as well. Evaluation of melasma lesions was performed before each treatment session and 4 and 12 weeks after the final treatment.

Melasma area and severity index (MASI)

A modified MASI was used in our study [8]. The MASI is now widely applied as a semi-objective index for melasma evaluation. According to Kimbrough-Green and colleagues, the face is divided into four areas: forehead, right malar, left malar, and chin, 30, 30, 30, and 10 of the total face area, equivalently. The grade of melasma severity is determined according to three variables: the percentages of the total area involved, on a scale of 0 (no involvement) to 6 (90–100 % involvement); darkness, on a scale of 0 (absent) to 4 (maximum); and the homogeneity of hyperpigmentation, on a scale of 0 (minimal) to 4 (maximum). The MASI value was calculated according to the following equation:

$$\text{MASI} = 0.3(DF + HF)AF + 0.3(DMR + HMR)AMR \\ + 0.3(DML + HML)AML + 0.1(DC + HC)AC$$

where *D* is darkness, *H* is homogeneity, *A* is area, *F* is forehead, *MR* is right malar, *ML* is left malar, and *C* is chin.

The MASI score for each patient was evaluated before and after treatment by two blinded assessors, and the average value was taken.

Mean melanin index, erythema index, and the L*a*b* system

Melanin index (MI) and erythema index (EI) values of the lesion were measured using a Mexameter (MX-18, Courage-Khazaka Electronic, Cologne, Germany). Four to six fixed points in lesion were selected at the first measurement before treatment, as well as the fixed points in the normal skin. The patients' MI and EI of those fixed lesional points and the corresponding normal skin points were measured before each treatment and after the final treatment. The mean MI

and EI were relative index determined using the following algorithm:

$$\begin{aligned} \text{MeanMI} &= \sum (MILk - MINk) / P; \text{ MeanEI} \\ &= \sum (EILk - EINk) / P \end{aligned}$$

Where L is lesional skin, N is normal skin, K is code number of the points, and P is total number of the fixed measuring points of a patient.

For more-objective assessments of clinical outcome, the intensity of pigmentation and erythema of the lesions of all patients were quantitatively assessed by measuring skin reflectance using a tristimulus color analyzer (Chromometer CM-2600, Konica Minolta holdings, Inc., Tokyo, Japan) at the darkest area of the bilateral cheekbones before each treatment and after the final treatment. Mean value was calculated. The intensity of pigmentation and erythema was then expressed in the $L^*a^*b^*$ system in which colors were quantified according to three axes: white–black or lightness (L^*), red–green or chrome (a^*), and yellow–blue or hue (b^*).

The higher the L value is, the brighter the skin tone is. The b value decreases when erythema improves.

Positions of the points were recorded on a drawing of human face in the patient's case report form (CRF) to ensure that we were measuring the same position at each session. All the measurements were repeated for three times, and the average value was documented.

Physician's global assessment (PGA) and patients' self-assessment

Two blinded dermatologists assessed the outcome of the treatments according to the patients' images. Patients' subjective satisfaction with the results was collected at the final visit. Improvement of hyperpigmentation was scored as follows: 0 worsening of hyperpigmentation; 1, no change; 2, mild (lesion clearance < 25 %); 3, moderate improvement (lesion clearance 25–50 %); 4, good (lesion clearance 50–75 %); and 5, remarkable (lesion clearance > 75 %).

Recurrence and safety evaluation

Worsening of hyperpigmentation or enlargement of the lesions was considered as a relapse. Total recurrence rate was determined as the percentage of relapsed patients. To monitor epidermal barrier function, trans-epidermal water loss (TEWL) was measured with Tewameter (TM300, Chourage-Khazaka Electronic, Cologne, Germany) before and after treatment. Side effects as erythema, edema, desquamation, hyperpigmentation, hypopigmentation, and depigmentation were recorded during the entire study if anyone occurred. The visual analogue

scale (VAS), on a scale of 0 (no pain) to 10 (unbearable pain), was applied to assess the degree of pain of each patient.

Statistical analysis

Differences in mMI, mEI, MASI values L , a , and b values before and after the therapy were tested using the Wilcoxon signed-rank test. A multiple linear regression method was used to analyze the possible efficacy-related factors. All statistical analyses were performed using SPSS16.0 (SPSS Inc., Chicago, IL) software, and $p < 0.05$ was regarded as statistically significant.

Results

Twenty-seven patients (26 females, 1 male) aged 25 to 53 (39.0 ± 8.3) underwent all the treatment sessions, and the 4-week and 12-week follow-ups and three cases dropped out. Seventeen patients completed the 24-week follow-ups. The duration of the disease varied from 1.3 to 20 (6.66 ± 4.87) years.

Clinical improvement

Melasma improved slightly after each treatment session, and noticeable improvement could usually be observed after three to four treatment sessions. Thereafter, continuous improvement was seen after each treatment sessions, as shown in Fig. 1.

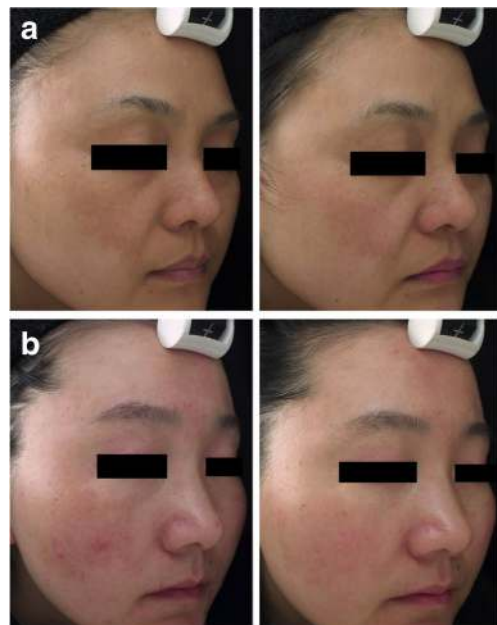


Fig. 1 **a** Significant improvement was observed after eight treatment sessions. **b** Improvements were observed both on hyperpigmentation and vasculature

Melasma area and severity index (MASI)

Mean MASI score decreased dramatically, from 12.84 ± 6.89 before treatment to 7.29 ± 4.15 4 weeks after the final treatment ($Z = -4.541, p < 0.01$), with 43 % improvement from the baseline MASI score. Seventy percent of patients got moderate to good improvements after all the treatment (Table 1).

Mean melanin index (MI) and erythema index (EI) changes

Mean MI decreased with time (Fig. 2a), changes paralleled the clinical improvement. It decreased significantly from 56.52 ± 23.35 to 32.75 ± 12.91 4 weeks after treatment compared with that pretreatment ($Z = -4.514, p < 0.01$). Mean EI also decreased significantly from 85.48 ± 39.84 to 66.55 ± 40.53 (Fig. 2b, $Z = -2.571, p < 0.05$). Furthermore, the results from multiple linear regression showed that the mean MI after the last treatment was positively correlated with the MI at baseline ($p < 0.01, R = 0.765$, standardized coefficients = 0.739), while the mean EI and MI at baseline showed no positive correlation ($p = 0.241, R = 0.765$, standardized coefficients = 0.158), which indicates that, the more severe the melasma, the worse the clinical response and the redness of the lesion does not affect the clinical response, though it decreased significantly after treatment.

L-a-b value changes

At the darkest point of each melasma lesion, the lightness of pigmentation (*L* value) increased from 59.21 ± 2.22 before treatment to 61.60 ± 2.40 4 weeks after the final treatment ($Z = -5.004, p < 0.01$) (Fig. 3a). The *a* value, reflecting the redness of the skin, decreased slightly from 12.62 ± 1.98 before treatment to 11.84 ± 1.88 4 weeks after treatment; however, this change was statistically significant ($Z = -2.355, p < 0.05$) (Fig. 3b). The *b* value, which reflects the yellowness of the skin, barely changed (20.16 ± 1.89 to $20.12 \pm 2.00, p = 0.493$) (Fig. 3c). Furthermore, the results from multiple linear regression also showed a positive correlation between mean *L* value after the last treatment and that at baseline ($p < 0.01, R = 0.841$, standardized coefficients = 0.991), while the *L* value after the last treatment and *a* value at baseline showed no positive correlation ($p = 0.085, R = 0.7841$, standardized coefficients = 0.264). Which reveals that efficacy was related with the intensity of pigmentation rather than redness of the skin.

Table 1 Improvement rates of MASI after treatment

	Remarkable	Good	Moderate	Mild	No change
	>75 %	50–75 %	25–50 %	<25 %	0
Number of patients (%)	1 (4 %)	10 (37 %)	9 (33 %)	7 (26 %)	0

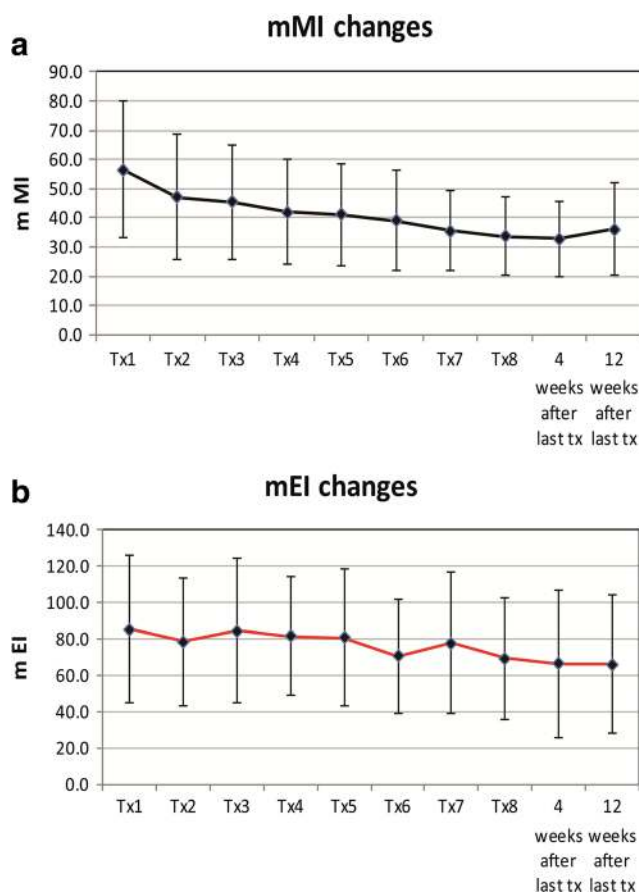


Fig. 2 **a** The mean MI decreased during and 4 weeks after the therapy. A slight increase was detected at 12 weeks after the last treatment. **b** The mean EI declined 4 weeks after the therapy, and there was no obvious increase at 12 weeks after the last treatment

Physician's global assessment and patients' self-assessment

The mean score of PGA was 3.76 ± 0.71 , revealing a “moderate” clearance of the lesion. In patients' self-evaluations, seven (26 %) patients rated the result as remarkable, 12 (44 %) assessed their improvement as “good,” five (18 %) rated their improvement as “moderate,” and three (10 %) reported “poor” improvement. The effective rate of this study was 70 % ($n = 19$).

Recurrence

At the 3-month follow-up visit, 11 patients had a relapse of the disease, a partial recurrence rate of 40 %. No worsening of hyperpigmentation was observed compared to that at the baseline, the complete recurrence rate being zero. Fourteen out of

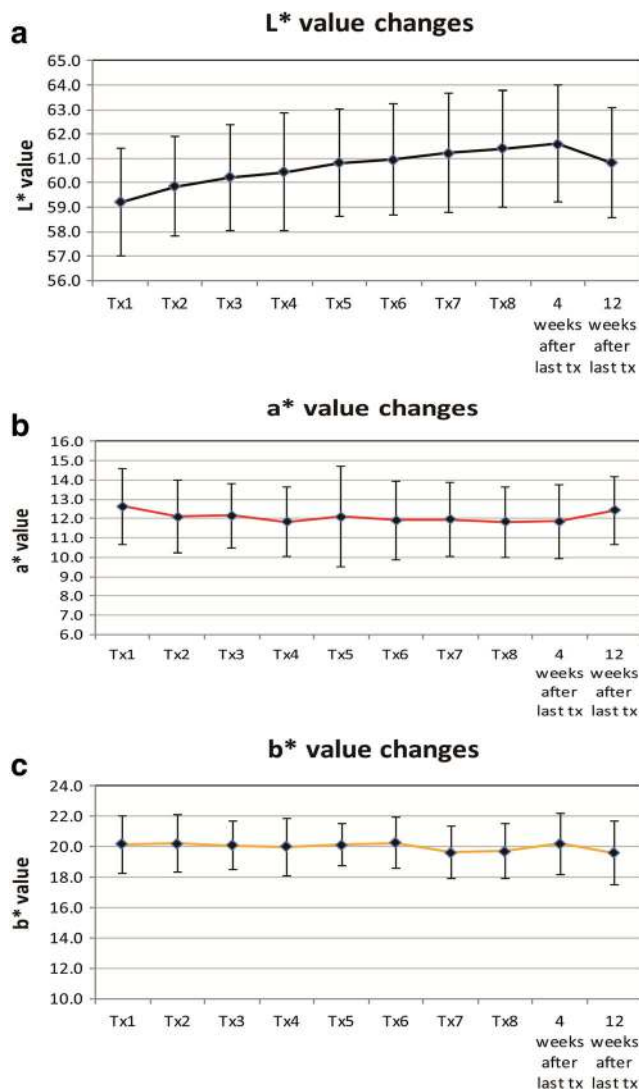


Fig. 3 **a** The mean L value increased during the therapy and 4 weeks after the treatment. It decreased slightly 12 weeks after the treatment but still higher than that of the baseline. **b** The mean a value decreased 4 weeks after the treatment while increased slightly 12 weeks after the treatment but still lower than that of the baseline. **c** The mean b value had almost no change during and after the treatment

17 patients had a relapse at the 6-month follow-up, a partial recurrence rate 82.4 %. Two patients had aggravated melasma, the complete recurrence rate being 11.8 %, one may be related to a thyroid dysfunction and the other may be caused by excess sun exposure without protection.

Adverse effects

All of the patients had a slight burning or tingling sensation at the laser treated area during the treatment, which was well tolerated. The VAS being 1.19 ± 0.40 on average. Slight erythema was observed after the treatment session and disappeared spontaneously in less than 2 hours. Postinflammatory hyperpigmentation, hypopigmentation, and punctate

leucoderma were not observed during the study. There were no other server adverse effects such as edema, scarring, and desquamation either. Transepidermal water loss (TEWL) did no change 4 weeks after treatment ($Z = -0.444$, $p = 0.657$) (Fig. 4), and we even can see it decreased slightly 12 weeks after the last treatment.

Discussion

The efficacy of Q-switched (QS) laser treatment for pigmented lesions is based on the theory of selective photothermolysis proposed by Anderson and Parrish [14]. However, QS laser such as QS ruby laser, QS alexandrite laser, and QS erbium:yttrium aluminum-garnet showed no beneficial effect to melasma and sometimes even causes worsening of the pigmentation [5]. The large-spot-size, low-fluence-mode application of the 1064-nm QS Nd:YAG laser is now a widely used therapy for melasma, especially in Asians. The parameters used are spot size of 6–8 mm in diameter and fluence of 1.6–3.4 J/cm², and scanning is repeated for several passes until the treatment end point of slight to mild erythema appeared. Each patient underwent multiple treatment session. In our previous study [8], we treated 50 Chinese patients with melasma weekly, and at the end of the clinical study (the tenth week), the MASI score decreased more than 50 % in 70 % of patients, and 10 % achieved complete clearance. In the study conducted by Cho et al. [9], 11 of the 25 patients (44 %) had marked clinical improvement: 7 (28 %) had near-total clinical improvement, 5 had moderate clinical improvement, and 2 had minimal to no improvement 2 months after treatment. Several studies also demonstrated satisfactory outcome [10–12]. However, according to our study and clinical practice, recurrence rate was high if weekly treatment was done with relatively high fluence. The risk of hyperpigmentation increases with the number of treatment. The recurrence rates at the 3-month follow-up was 64 % [8] in our previous study. Evidence of melasma flare was

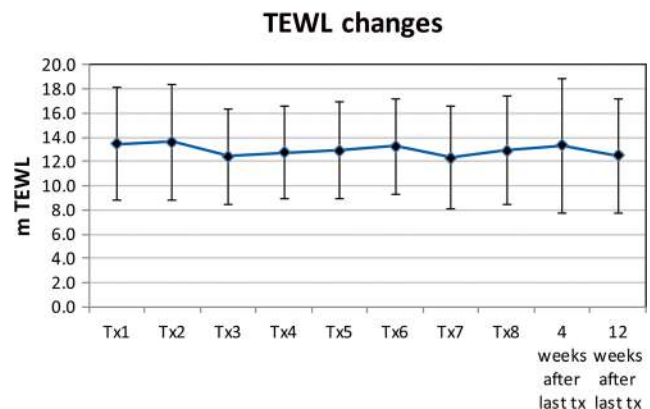


Fig. 4 The mean TEWL fluctuated during the treatment, while it barely increased when compared with the baseline

common at 3-month after last treatment in a study by Brown et al. [13]. Furthermore, the exact recurrence rates were not reported in each study, and long-term follow-ups are still need.

Melanocytes in melasma lesions are believed to be overactive in function and easily stimulated. Evidence showed that low-fluence QS Nd:YAG laser was an effective therapy treating melasma through subcellular-selective photothermolysis. Mun et al. [6] revealed that in the epidermis, fewer dendrites in the melanocytes were observed after laser treatment compared with pretreatment and laser treatment caused selective photothermolysis on stage IV melanosome detected by transmission electron microscopy. Based on results using an adult zebrafish model, Kim et al. [7] found that melanocytes are still able to survive despite melanosomal destruction but are functionally suppressed and melanogenesis was inhibited. Therefore, clinical improvement was observed. However, depigmentation was likely to occur after repeated treatment despite subcellular-selective photothermolysis. Researchers reported that low-fluence Nd:YAG laser might form punctate leucoderma due to photodamage to melanocytes resulting in melanocytopenic hypopigmentation [15, 16], that may be caused by accumulated energy of multiple treatment sessions, overlapping exposure to laser irradiation, or higher pulse energy. It is observed that the more sessions of treatment, the higher is the risk of leucoderma. Therefore, treatment sessions and fluence should be limited in order to prevent punctate leucoderma.

Nonablative fractional lasers, such as 1540-nm Er Glass fractional laser and 1550-nm erbium-doped fractional lasers, have also been used in recent years for the treatment of melasma, and there have been reported successful treatments [17]. Nevertheless, some authors have been reserved in this view and found that nonablative fractional lasers could not provide a substantial benefit in treating melasma [18]. These laser modalities are not melanin selective, yet fractional mode lasers have certain advantages in that they save untreated areas between microscopic treatment zones (MTZs), allowing for rapid healing shorter recovery times [17], and hence less inflammation.

Some recent studies [19, 20] also demonstrated that 694-nm fractional QS Ruby laser was effective for melasma for patients with Caucasian or Asian skin types without obvious side effects such as scarring or postinflammatory hyper- or hypopigmentation, indicating that the combination of fractional mode and QS lasers may be helpful in the treatment of melasma.

In this study, the advantages of fractional mode were combined with those of large-spot low-fluence QS Nd:YAG laser treatment in hope of achieving prolonged improvement. In order to achieve desired clinical outcomes, multiple scanning passes in each session and multiple treatment sessions are required. Hyperpigmentation or hypopigmentation was not observed in our study; this may be attributed to the fractional

mode, in which the melanocytes received lower cumulative energy than the total toxic energy that stimulates or damages melanocytes causing hyperpigmentation or hypopigmentation.

Studies have shown that melasma lesion is also characterized by an increased vasculature clinically and histologically [21, 22]. The expression of VEGF, a major angiogenic factor in UV-irradiated skin, which is known to stimulate the release of arachidonic acid and the phosphorylation and activation of cytosolic phospholipase A2, affecting melanogenesis via the arachidonic acid pathway, is upregulated in melasma [22]. Furthermore, there was a significant relationship between the number of vessels and pigmentation in melasma, indicating that a prominent vasculature accompanies hyperpigmentation. In our present study, both EI and *a* value decreased after treatment, while they did not positively correlate to the efficacy. The reduction of vasculature may be help to downregulate melanogenesis which leads to longer maintenance of the clinical results and providing an improved appearance.

TEWL was not increased significantly after treatment in this study, showing that the epidermal barrier function of the treated area was not irreversibly impaired. Lee et al. [23] found a delayed barrier recovery rate in melasma skin, which should be considered when treating melasma. The rapid recovery of barrier function also plays an important role in lowering the recurrence rate.

In conclusion, Pixel QS Nd:YAG laser therapy is efficacious for the treatment of melasma. Although the efficacy is no better than the conventional low-fluence QS Nd:YAG laser, recurrence rate of this therapy is much lower than the conventional ones and the procedure proved to be safe. Adjuvant therapies may help improve the efficacy and maintenance of the treatment results.

Acknowledgments The authors would like to thank Ms. Yue Hu (Dermatology, Huashan Hospital) for her assistance of the skin measurements of the trial.

References

1. Sheth VM, Pandya AG (2011) Melasma: a comprehensive update: part I. *J Am Acad Dermatol* 65(4):689–697, quiz 698
2. Grimes PE (1995) Melasma. Etiologic and therapeutic considerations. *Arch Dermatol* 131(12):1453–1457
3. Niepomniszcze H, Amad RH (2001) Skin disorders and thyroid diseases. *Journal of Endocrinological Investigation* 24(8):628–638
4. Gupta AK, Gover MD, Nouri K, Taylor S (2006) The treatment of melasma: a review of clinical trials. *J Am Acad Dermatol* 55(6): 1048–1065
5. Sheth VM, Pandya AG (2011) Melasma: a comprehensive update: part II. *J Am Acad Dermatol* 65(4):699–714, quiz 715
6. Mun JY, Jeong SY, Kim JH, Han SS, Kim IH (2011) A low fluence Q-switched Nd:YAG laser modifies the 3D structure of melanocyte and ultrastructure of melanosome by subcellular-selective photothermolysis. *J Electron Microscop* (Tokyo) 60(1):11–18

7. Kim JH, Kim H, Park HC, Kim IH (2010) Subcellular selective photothermolysis of melanosomes in adult zebrafish skin following 1064-nm Q-switched Nd:YAG laser irradiation. *J Invest Dermatol* 130(9):2333–2335
8. Zhou X, Gold MH, Lu Z, Li Y (2011) Efficacy and safety of Q-switched 1,064-nm neodymium-doped yttrium aluminum garnet laser treatment of melasma. *Dermatol Surg* 37(7):962–970
9. Cho SB, Kim JS, Kim MJ (2009) Melasma treatment in Korean women using a 1064-nm Q-switched Nd:YAG laser with low pulse energy. *Clin Exp Dermatol* 34(8):e847–e850
10. Suh KS, Sung JY, Roh HJ, Jeon YS, Kim YC, Kim ST (2011) Efficacy of the 1064-nm Q-switched Nd:YAG laser in melasma. *J Dermatolog Treat* 22(4):233–238
11. Wattanakrai P, Mornchan R, Eimpunth S (2010) Low-fluence Q-switched neodymium-doped yttrium aluminum garnet (1,064 nm) laser for the treatment of facial melasma in Asians. *Dermatol Surg* 36(1):76–87
12. Sim JH, Park YL, Lee JS et al (2014) Treatment of melasma by low-fluence 1064 nm Q-switched Nd:YAG laser. *J Dermatolog Treat* 25(3):212–217
13. Brown AS, Hussain M, Goldberg DJ (2011) Treatment of melasma with low fluence, large spot size, 1064-nm Q-switched neodymium-doped yttrium aluminum garnet (Nd:YAG) laser for the treatment of melasma in Fitzpatrick skin types II-IV. *J Cosmet Laser Ther* 13(6):280–282
14. Anderson RR, Parrish JA (1983) Selective photothermolysis: precise microsurgery by selective absorption of pulsed radiation. *Science* 220(4596):524–527
15. Kim MJ, Kim JS, Cho SB (2009) Punctate leucoderma after melasma treatment using 1064-nm Q-switched Nd:YAG laser with low pulse energy. *J Eur Acad Dermatol Venereol* 23(8):960–962
16. Kim T, Cho SB, Oh SH (2010) Punctate leucoderma after 1,064-nm Q-switched neodymium-doped yttrium aluminum garnet laser with low-fluence therapy: is it melanocytopenic or melanopenic? *Dermatol Surg* 36(11):1790–1791
17. Kroon MW, Wind BS, Beek JF et al (2011) Nonablative 1550-nm fractional laser therapy versus triple topical therapy for the treatment of melasma: a randomized controlled pilot study. *J Am Acad Dermatol* 64(3):516–523
18. Karsai S, Fischer T, Pohl L et al (2012) Is non-ablative 1550-nm fractional photothermolysis an effective modality to treat melasma? Results from a prospective controlled single-blinded trial in 51 patients. *J Eur Acad Dermatol Venereol* 26(4):470–476
19. Jang WS, Lee CK, Kim BJ, Kim MN (2011) Efficacy of 694-nm Q-switched ruby fractional laser treatment of melasma in female Korean patients. *Dermatol Surg* 37(8):1133–1140
20. Hilton S, Heise H, Buhren BA, Schrupf H, Bolke E, Gerber PA (2013) Treatment of melasma in Caucasian patients using a novel 694-nm Q-switched ruby fractional laser. *Eur J Med Res* 18:43
21. Kim EH, Kim YC, Lee ES, Kang HY (2007) The vascular characteristics of melasma. *J Dermatol Sci* 46(2):111–116
22. Kang HY, Bahadoran P, Suzuki I et al (2010) In vivo reflectance confocal microscopy detects pigmentary changes in melasma at a cellular level resolution. *Exp Dermatol* 19(8):e228–e233
23. Lee DJ, Lee J, Ha J, Park KC, Ortonne JP, Kang HY (2012) Defective barrier function in melasma skin. *J Eur Acad Dermatol Venereol* 26(12):1533–1537