

# THERAPEUTIC HOTLINE

## Treatment of keloids with laser-assisted topical steroid delivery: a retrospective study of 23 cases

MARINE CAVALIÉ\*, LAURA SILLARD\*, HENRI MONTAUDIÉ\*,  
PHILIPPE BAHADORAN\*, JEAN-PHILIPPE LACOUR\*, &  
THIERRY PASSERON\*†

*\*Department of Dermatology, University Hospital of Nice and †Centre Méditerranéen de Médecine Moléculaire (C3M), Team 12, U1065, INSERM, Nice, France*

**ABSTRACT:** Topical or intralesional corticosteroids are referred to as gold standard treatments for keloids. Recent studies showed that ablative fractional laser (AFL) treatment facilitates delivery of topical drug deeply into the skin by creating vertical channels. The objective of the present study was to assess the ablative erbium laser in fractionated mode, combined with topical high potent corticosteroid cream for treating resistant keloid scars. We conducted a retrospective study in the laser center of the Department of Dermatology (University Hospital of Nice, France), from January 2010 to June 2012, on patients with keloids who were resistant to a first-line of treatment. A 2940-nm ablative fractional erbium laser was used. Topical betamethasone cream was applied twice a day under occlusion with transparent film dressings. A total of 23 patients with 70 keloids were treated from January 2010 to June 2012. The median percentage of improvement was 50% (range –43 to 84). The mean follow-up was 8 months (range 3–18), and a recurrence was observed for eight lesions (22%). Although this observation warrants a prospective comparative evaluation, it supports the interest of the laser-assisted delivery of steroids for treating keloids scars.

**KEYWORDS:** ablative fractional laser, keloid treatment, laser-assisted drug delivery, topical corticosteroids, transepidermal drug delivery

### Introduction

Keloids result from an overgrowth of dense fibrous tissue on the skin. Often viewed as esthetically displeasing, they are among the most common and frustrating problems after surgery or injury,

causing functional and cosmetic deformities, discomfort, itching, pain, and psychological stress. Consequently, the quality of life of affected individuals is impaired (1). Keloids remain notoriously difficult to eradicate and show high recurrence rates. Steroids, applied topically or injected into the lesion, are considered to be one of the best treatment options, but their effectiveness is limited. Alternative treatments for keloids include surgical excision or intralesional therapies: 5-fluorouracil (5-FU), bleomycin and interferon, topical imiquimod, compression, cryotherapy, radiation, silicon sheeting, and laser- or light-based therapies.

Address correspondence and reprint requests to: Thierry Passeron, MD, PhD, Professor of Dermatology, Head of Team 12, U1065, C3M, Hôpital de l'Archet 2, service de dermatologie, 151, Route St Antoine de Ginestière, 06200 Nice, France, or email: [passeron@unice.fr](mailto:passeron@unice.fr).

The outermost layer of the skin, the stratum corneum, is the most significant barrier to percutaneous drug absorption. Fractional ablative lasers create vertical channels in the skin referred to as a microthermal zone that facilitates topical drug delivery deep into the skin. Laser-assisted drug delivery is an alternative to injection or other drug delivery methods into skin lesions (2). Laser-assisted drug delivery has been shown to enhance photosensitizer penetration in photodynamic therapy (3–5) as well as the penetration of topical anesthetics (6), opioids (7), nonsteroidal anti-inflammatory drugs (8) or chemotherapeutic drugs such as 5-FU (9) or imiquimod (10). The objective of this study was to assess the ablative erbium laser in fractionated mode combined with topical high potent corticosteroid cream to treat resistant keloid scars.

## Materials and methods

We conducted a retrospective study in the Department of Dermatology (University Hospital of Nice, France), from January 2010 to June 2012, on patients with keloids that were resistant to first-line treatment (e.g., intralesional corticosteroid, surgery, silicon sheets). Patients with hypertrophic scars were not included. A 2940-nm ablative fractional erbium laser (Burane XL, Alma Laser, Erlangen, Germany) was used (180 J/cm<sup>2</sup>, no coagulation, 5% coverage). Analgesia was provided with pulsed cold air combined with local application of lidocaine cream applied 1 hour before the sessions. Topical betamethasone cream was applied twice a day under occlusion with transparent film dressings. The patients had one laser session every other week with four crossed passes for a total of 20% coverage. Sessions were performed until complete flattening of the scars was achieved and were discontinued when no further improvement was observed. The efficacy of the treatment was evaluated on digital pictures by two independent physicians. They made a comparative evaluation of the evolution of the lesions by rating the percentage of improvement or worsening on two standardized pictures; pre- and posttreatment pictures were scrambled. Patient satisfaction was evaluated on a visual analog scale from 0 (*not satisfied at all*) to 10 (*very satisfied*).

## Results

The results are summarized in Table 1. A total of 23 patients with 70 keloids were treated. The medium

age was 30 years (range 12–51). Seven (30%) were women, and 16 (70%) were men. Thirty-four keloids were on the chest (FIG. 1), 18 on the shoulders or arms, nine on the face (FIG. 2), five on the ears, and four on the neck. Twenty-eight keloids were secondary to acne, 28 were spontaneous, and 14 were posttraumatic. A median of nine sessions (range 3–29) was performed. The median percentage of improvement was 50% (range –43% to 84%). Four lesions (two patients) worsened during treatment. The improvement was higher for post-acne keloids (median improvement of 77%). The improvement on ear and neck keloids was poor, with a median amelioration of 8%. The median satisfaction rate of the patients was 7/10 (range 3–10). Pain during the sessions was evaluated at 5/10 (range 0–10). Side effects were hypochromia that normalized 1 month after the end of the treatment and that was observed only in darker skin types (5/70), eczematiform reaction to the occlusive film (3/70), and folliculitis (3/70). The patients who improved were asked to return for a follow-up visit. Thirteen patients with a total of 36 keloids returned. With a mean follow up of 8 months (range 3–18), a recurrence, defined as a return to baseline, was observed for eight keloids (22%).

## Discussion

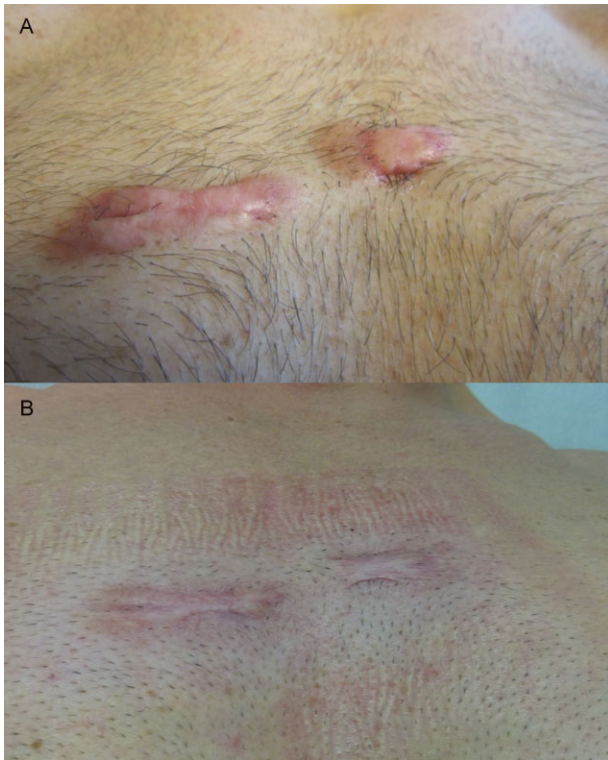
The advent and development of laser technology may represent the most promising treatment method for the cosmetic and functional improvement of cutaneous scars. Several types of lasers have been reported to improve scars, but keloids are by far the most difficult type of scars to treat. Pulsed-dye lasers (PDL) produce selective photothermolysis of small blood vessels causing destruction of the microvasculature of the scar. Based on the principle that vascular proliferation plays a key role in the early phase of hypertrophic scar formation, PDL has been shown to improve erythema and the texture of keloids and hypertrophic scars (11). PDL can also be useful in preventing the formation of keloid scars after surgery (12). The 1064-nm Nd : YAG laser and the intense pulsed light have also been reported to allow a cosmetic improvement of keloids (13). Ablative lasers, such as the 2940-nm erbium-doped: yttrium, aluminum, and garnet (Er : YAG) laser and the 10 600 nm carbon dioxide (CO<sub>2</sub>) laser, emit beams absorbed by water in skin, resulting in local tissue destruction. Carbon dioxide laser monotherapy can successfully ablate keloids, but this therapy is associated with high recurrence rates, which may

**Table 1.** Description of the population, clinical characteristics of the keloids and percentage improvement after treatment

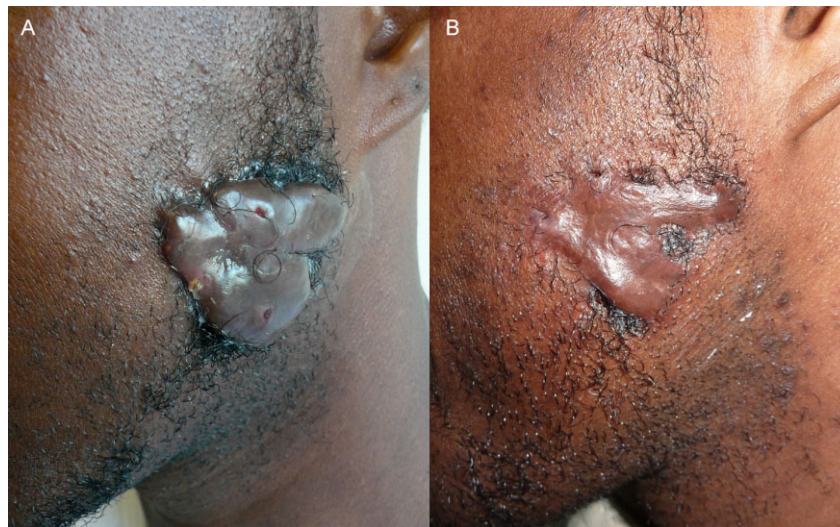Gender	Age (years)	Phototype	Former treatment	Localization	Context	Number of keloids	Number of sessions	Time of treatment (weeks)	Percentage of amelioration: observer 1	Percentage of amelioration: observer 2	Patient satisfaction (/10)	Follow-up (months)	Relapse
M	36	V	Intralesional injections of bleomycin	Cheeks	Spontaneous	2	25	110, 3	75%, 80%	70%, 70%	10'	6	No
F	29	V	Surgery	Arm	Burn injury	3	11	48, 6	80%, 50%, 90%	60%, 50%, 75%	7	18	No
M	38	IIIa	Intralesional injections of corticosteroids	Chest	Spontaneous	2	25	70, 6	70%, 70%	75%, 75%	8	6	No
M	19	IIIa	Topical applications of corticosteroids	Chest + earlobe	Surgery/piercing	2	7	13, 6	20%, 20%	35%, 10%	7	12	Yes
F	26	II	Topical applications of corticosteroids	Chest	Spontaneous	1	4	8, 6	75%	35%	6	12	No
M	46	IIIa	Surgery	Earlobe	Piercing	1	7	14, 6	0%	-20%	7	6	Yes
F	23	IIIa	Intralesional injections of bleomycin	Shoulders	Spontaneous	3	3	59, 3	0%	5%, 0%, 20%	3	-	-
M	26	II	Surgery, laser, intralesional injections of corticosteroids	Cheek	Spontaneous	1	6	15, 0	72%	45%	8	5	Yes
M	42	IV	Intralesional injections of bleomycin	Chest	Spontaneous	2	10	32, 0	70%, 80%	55%, 55%	5	7	No
M	43	IV	Intralesional injections of corticosteroids	Jaw	Spontaneous	1	5	13, 0	50%	40%	7	12	Yes
M	30	V	None	Neck	Spontaneous	1	16	30, 7	0%	30%	7	-	-
M	29	V	Intralesional injections of corticosteroids	Chest	Spontaneous	6	18	45, 0	0%*6	20%*6	7	3	No
M	23	IV	Intralesional injections of bleomycin	Neck	Spontaneous	3	12	76, 0	-30%, -50%, -60%	-35%, -30%, -50%	5	-	-
F	25	IIIa	Isotretinoin	Cheeks	Post acne	5	3	5, 0	0%*5	10%*5	3	-	-
F	57	IIIa	Laser	Breasts	Post mammoplasty	4	3	30, 7	70%, 50%, 0%, 0%	60%, 30%, 0%, 0%	4	-	-
M	19	II	Intralesional injections of corticosteroids	Chest	Post acne	10	5	16, 0	78%*10	70%*10	7	6	No
M	25	IIIb	Surgery	Shoulder + earlobe	Spontaneous	2	9	25, 7	0%, 50%	15%, 15%	4	-	-
F	12	IIIa	Surgery	Retroauricular	Post otoplasty	2	7	20, 7	30%, 30%	30%, 30%	5	-	-
F	46	IIIa	Topical applications of corticosteroids	Shoulder	Spontaneous	1	10	27, 7	0%	0%	8	-	-
M	20	IV	Intralesional injections of corticosteroids	Back	Post acne	5	3	19, 7	95%*5	73%*5	7	-	-
F	52	IIIa	Silicone sheets	Nipple + chest	Post surgery	2	9	19, 7	10% flanc, 0%	15%, 0%	7	6	No
F	20	II	Intralesional injections of corticosteroids	Back	Post acne	8	5	12, 0	93%*8	65%*8	8	-	-
M	36	IIIa	Intralesional injections of corticosteroids	Chest	Spontaneous	3	9	18	60%, 60%, 60%	75%, 80%, 60%	6	3	Yes

be due to incomplete removal of keloidal fibroblasts (13). The use of these ablative lasers in fractional mode represents a promising tool in the treatment of scars with minimal pain and rapid wound healing in a few days (14). Beyond the specific action of these lasers on scar remodeling, the

channels that they create can be used to deliver agents within the keloid and to potentiate their efficacy. A recent pilot study showed interesting results in the treatment of hypertrophic scars by combining an ablative fractional laser and triamcinolone acetonide suspension immediately after laser therapy (15). Ablative fractional radiofrequency associated with acoustic pressure ultrasound was also used to increase triamcinolone delivery into hypertrophic scars. This new method showed significant improvements in the four treated patients (16). To the best of our knowledge, no study has assessed the combination of topical steroid and ablative fractional lasers or radiofrequencies in the treatment of keloids, which remain the most difficult type of scar to treat. Although our results warrant a prospective comparative evaluation, they support the laser-assisted delivery of steroids for keloid scar treatment. Our study shows that this approach seems to be more effective on post-acne keloids, while results are disappointing for keloids on the ears and neck. These differences could be due to the difficulty in applying topical steroids under occlusion in these sites. Side effects were limited and all transient. Interestingly, the patients were mostly satisfied by the improvement of the consistency of the keloids and of the associated symptoms (itching and pain). This was correlated with relatively high patient satisfaction. The recurrence rate was approximately 25%. Thus, patients should be warned about the potential risk of relapse. The recurrence rates were lower in patients who had more than 10 sessions, which may suggest that a maintenance treatment



**FIG. 1.** Spontaneous keloid of the chest (A) before treatment, (B) after 25 sessions of ablative fractional laser combined with topical betamethasone.



**FIG. 2.** Spontaneous keloid of the left cheek (A) before treatment, (B) after 25 sessions of ablative fractional laser combined with topical betamethasone.



could prevent these recurrences. Interestingly, all the recurrences occurred in the first 2 months after the end of the sessions.

Many questions remain, such as the optimal laser and parameters to use, schedule of treatment, and choice of steroids, but the results herein suggest that ablative fractional lasers could be an effective tool to enhance the effectiveness of topical steroids to treat dermatological conditions.

## References

- Balci DD, Inandi T, Dogramaci CA, et al. DLQI scores in patients with keloids and hypertrophic scars: a prospective case control study. *J Dtsch Dermatol Ges* 2009; **7**: 688–692.
- Sklar LR, Burnett CT, Waibel JS, et al. Laser assisted drug delivery: a review of an evolving technology. *Lasers Surg Med* 2014; **46**: 249–262.
- Togsverd-Bo K, Haak CS, Thaysen-Petersen D, et al. Intensified photodynamic therapy of actinic keratoses with fractional CO2 laser: a randomized clinical trial. *Br J Dermatol* 2012; **166**: 1262–1269.
- Haedersdal M, Katsnelson J, Sakamoto FH, et al. Enhanced uptake and photoactivation of topical methyl aminolevulinate after fractional CO2 laser pretreatment. *Lasers Surg Med* 2011; **43**: 804–813.
- Helsing P, Togsverd-Bo K, Veierod MB, et al. Intensified fractional CO2 laser-assisted photodynamic therapy vs. laser alone for organ transplant recipients with multiple actinic keratoses and wart-like lesions: a randomized half-side comparative trial on dorsal hands. *Br J Dermatol* 2013; **169**: 1087–1092.
- Yun PL, Tachihara R, Anderson RR. Efficacy of erbium : yttrium–aluminum–garnet laser-assisted delivery of topical anesthetic. *J Am Acad Dermatol* 2002; **47**: 542–547.
- Lee WR, Shen SC, Fang CL, et al. Skin pretreatment with an Er : YAG laser promotes the transdermal delivery of three narcotic analgesics. *Lasers Med Sci* 2007; **22**: 271–278.
- Bachhav YG, Heinrich A, Kalia YN. Using laser microporation to improve transdermal delivery of diclofenac: increasing bioavailability and the range of therapeutic applications. *Eur J Pharm Biopharm* 2011; **78**: 408–414.
- Gomez C, Costela A, Garcia-Moreno I, et al. Laser treatments on skin enhancing and controlling transdermal delivery of 5-fluorouracil. *Lasers Surg Med* 2008; **40**: 6–12.
- Lee WR, Shen SC, Al-Suwayeh SA, et al. Laser-assisted topical drug delivery by using a low-fluence fractional laser: imiquimod and macromolecules. *J Control Release* 2011; **153**: 240–248.
- Alster TS, Williams CM. Treatment of keloid sternotomy scars with 585 nm flashlamp-pumped pulsed-dye laser. *Lancet* 1995; **345**: 1198–1200.
- Manuskiatti W, Wanitphakdeedecha R, Fitzpatrick RE. Effect of pulse width of a 595-nm flashlamp-pumped pulsed dye laser on the treatment response of keloidal and hypertrophic sternotomy scars. *Dermatol Surg* 2007; **33**: 152–161.
- Mamalis AD, Lev-Tov H, Nguyen DH, et al. Laser and light-based treatment of keloids – a review. *J Eur Acad Dermatol Venereol* 2014; **28**: 689–699.
- Anderson RR, Donelan MB, Hivnor C, et al. Laser treatment of traumatic scars with an emphasis on ablative fractional laser resurfacing: consensus report. *JAMA Dermatol* 2014; **150**: 187–193.
- Waibel JS, Wulkan AJ, Shumaker PR. Treatment of hypertrophic scars using laser and laser assisted corticosteroid delivery. *Lasers Surg Med* 2013; **45**: 135–140.
- Issa MC, Kassuga LE, Chevrant NS, et al. Topical delivery of triamcinolone via skin pretreated with ablative radiofrequency: a new method in hypertrophic scar treatment. *Int J Dermatol* 2013; **52**: 367–370.