

The New Fashion Vectorial Way To Improve Fat Remodeling and Sculpting The Face Using Non Invasive In Motion Selective Ultrasound (Accent Ultra): 12 Months of Follow-Up

ALMEIDA GUILHERME, ALMEIDA LETICIA, MARQUES ELAINE

Sirio-Libanês Hospital São Paulo, Brazil
Clinica Dermatologica

Background and Objectives

Since the early days, the search for the perfect body has been sought. In a country like Brazil where the sun shines most of the year, the cult of the body is a fact.

The demand for a nonsurgical, noninvasive treatment of located fat has inspired some manufactures to invest in a new age of sophisticated devices and treatment therapies to repair the skin and improve contours.

The aim of this paper is to present a new vectorial fashion way to improve of fat remodeling and sculpting the face using the combination of non invasive in motion selective ultrasound (ACCENT ULTRA, Alma Lasers Ltd, Israel).

Study Design and Methods

Fifty patients with located fat on the submental and malar were treated (age 21 to 74).

The sessions with Ultra were separated by 14 days apart in a total of 3 treatments using the same parameters of 8 minutes and level 3 on submental and 4 minutes and level 5 each malar part.

Each patient's face cleaned and marked with cirurgical marker in 3 specific points (submental and malars). A coat of vaseline was spread evenly over the areas. After the procedure the areas were cleaned d dried.

Results were evaluated by standard and three-dimension photography (VECTRA 3D, Canfield) before and after treatments (0 day, 6 weeks, and 12 months).

Both patient and physician investigator evaluated the treatment using a grading scale of improvement ranging from I (no), II (less than 25%), III (26-50%), IV(51-75%), and V(76-100%). Only grades IV and V were considered satisfactory.

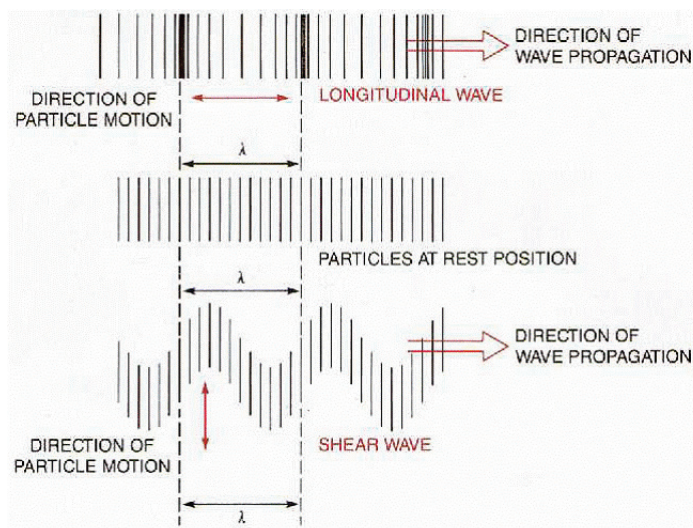


Figure 1
The particle movement responsible for the propagation of longitudinal and shear waves

In longitudinal waves, the oscillations occur in the longitudinal direction or the direction of wave propagation. Since compressional and dilational forces are active in these waves. They are also sometimes called density waves because their particle density fluctuates as they move

In the transverse or shear wave, the particles oscillate at a right angle or transverse to the direction of propagation.

Results

The mode of propagation of mechanical waves generated are called shear waves.

The shear waves histological damages the membrane of fat cells, repeatedly stretch and relax the adipocytes and causes disruption of that, damaging also the septa of the fat layer with no epidermal and dermal damage.

The mean patients rate of satisfaction with a grade IV and V was 70%.

No side effects were related to the treatment only 5 % of transitory redness and 10% of purpura.

Score of improvement	Patient's Assessment	Physician's Assessment
I (0)	0	0
II (<25%)	0	0
III (26 - 50%)	0	0
IV (51 - 75%)	12	4
V (76 -100%)	30	38

Table 1 . Score of improvement scale with I=non improvement (0%), II=minor improvement (1-25%), III=moderate improvement (26-50%), IV=marked improvemet (51-75%) and V=very significant improvement (76-100%) with patient's and physicians' assessment.

Conclusion

The treatment sessions with non invasive selective ultrasound produce fat remodeling and sculpting the face with efficiency and safety. Based on this good results, others protocols should be encouraged in view of the results are maintained over time.

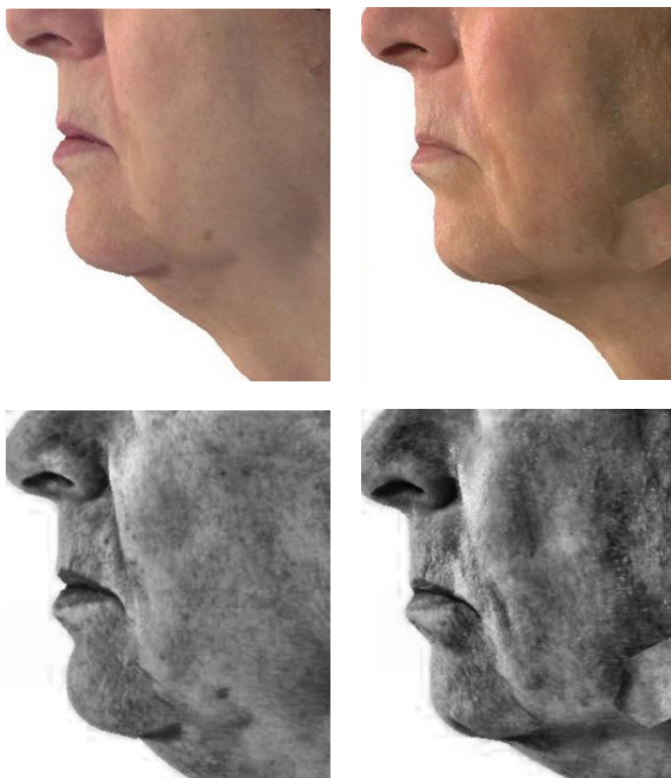


Figure 2: Baseline (A) and 12 months of ACCENT ULTRA (B) recorded with VECTRA 3D.

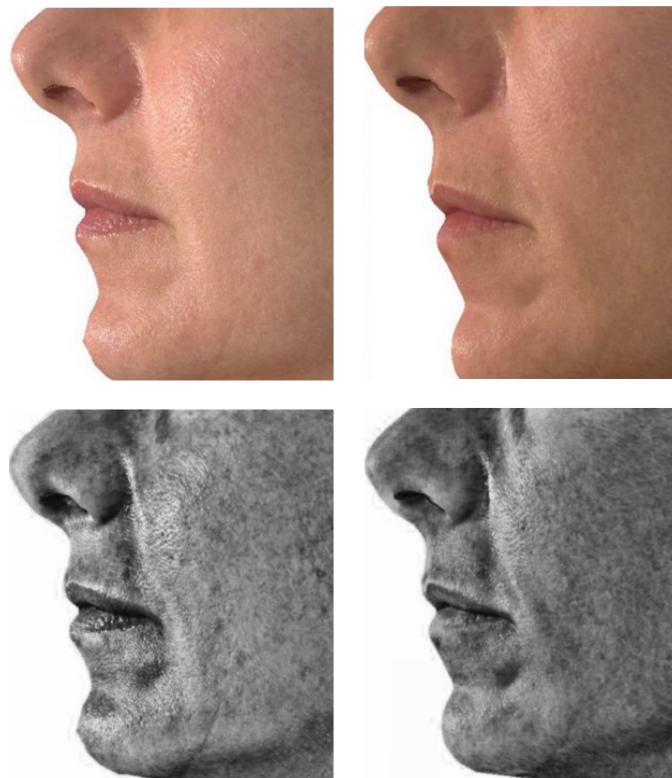

Figure 3: Baseline (A) and 12 months of ACCENT ULTRA (B) recorded with VECTRA 3D.

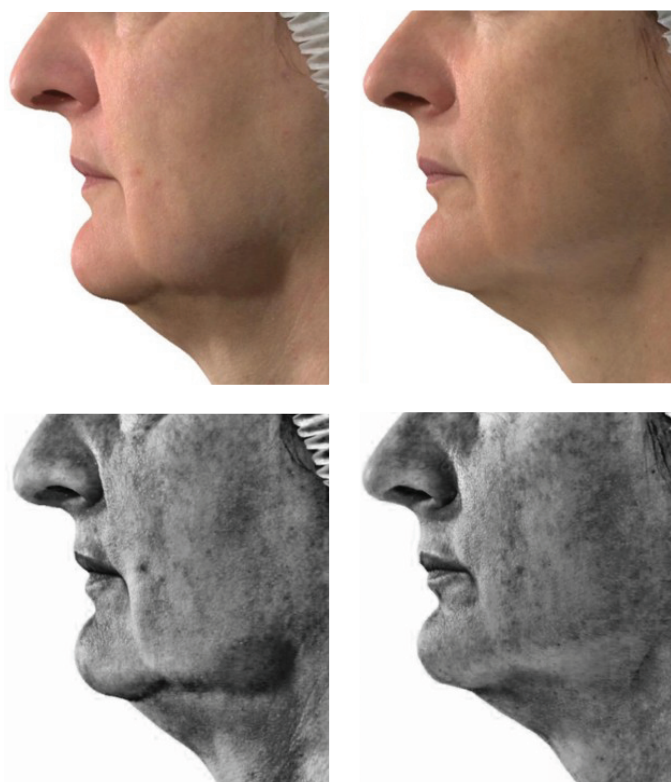

Figure 4: Baseline (A) and 12 months of ACCENT ULTRA (B) recorded with VECTRA 3D.

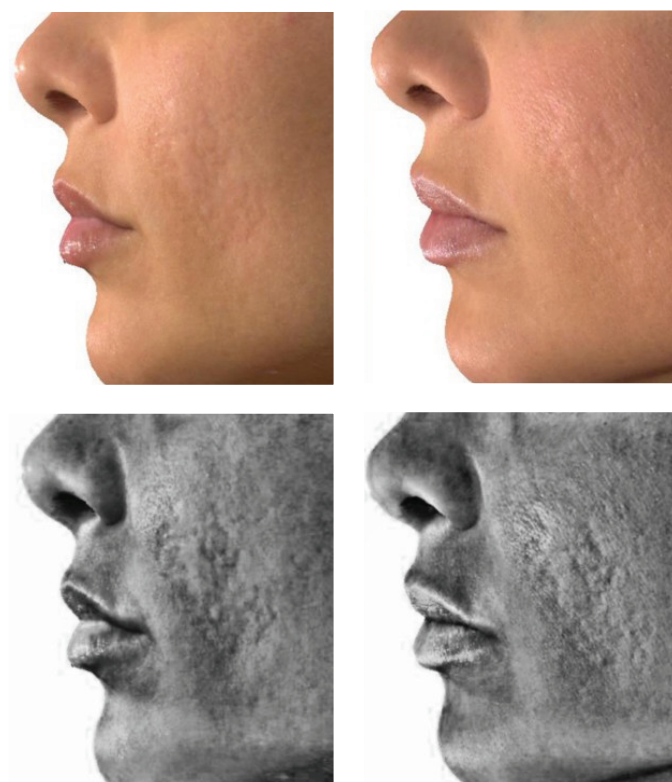

Figure 5: Baseline (A) and 12 months of ACCENT ULTRA (B) recorded with VECTRA 3D.