

# Ultrasound and Radio Frequency for Body Contouring Brazilian Experience

**Rafael Nunes, Daniela Nunes, Camara Luciana, Guilherme Nunes, Leticia Almeida Silva**

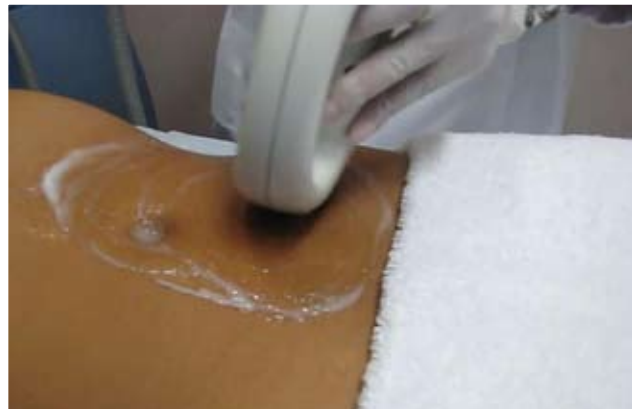Slim Clinique Laser Center and Bonsucesso Hospital – Dermatology Department, Rio de Janeiro, Brazil

## Abstract

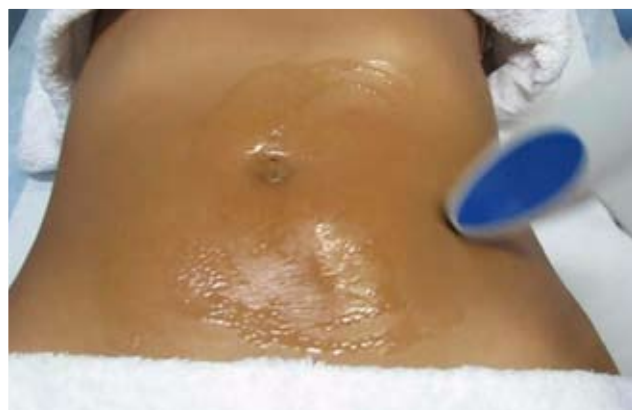A change in body contour is one of the most commonly requested results in daily practice, yet for many years only invasive treatments were available. This study presents a Brazilian experience with ultrasound and radio frequency technology (Accent™ Ultra, Alma Lasers Inc, Buffalo Grove, IL), a noninvasive body contouring technique. 24 subjects received the treatment. A total of 4 sessions were performed, 2 weeks apart, with great results and no adverse effect, proving the treatment to be safe and with high subject satisfaction.

## Background and Objectives

In Brazil, the desire for body contouring improvements is more popular than ever before. The use of ultrasound and radio frequency technology has become a common modality in the aesthetic market for non-invasive body contouring. The purpose of this study was to evaluate the efficiency and safety of this new technology in body contouring with a follow-up at the end of the 4<sup>th</sup> session and 3 months thereafter.



**Figure 1:** Ultrasound phase



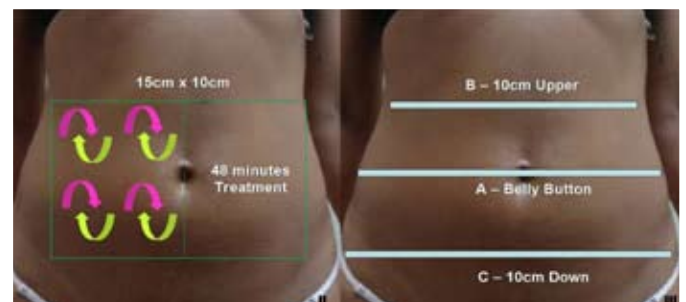
**Figure 2:** Radio frequency phase

## Study Design and Methods

24 subjects: 22 females, 2 males, 19-60 years old (average of 34), body mass index 23-30 (average of 26.3), treated area: abdomen - 2 areas of 15cmx10cm each divided into 4 smaller areas, all of which were treated during the same session. Subjects were treated in 4 sessions, spaced 2 weeks apart. Treatment protocol comprised alternate ultrasound shear waves followed by radio frequency waves. A coat of petroleum jelly was spread evenly over the entire area to enhance coupling. Each quadrant received alternately compression waves at a 1:3 ratio (5:15 seconds ratio) to the shear waves for a period of 6 minutes (Figure 3.II). After completion of the treatment, the 15cmx10cm grid area was cleaned and dried. Skin reaction during the treatment was a slight erythema and transient warmth.



**Figure 3.I:** Ultrasound module



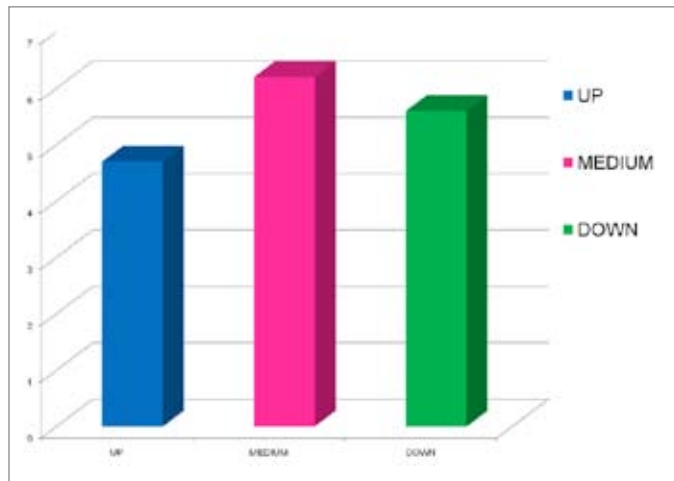
**Figure 3.II:** Handpiece movement technique

**Figure 3.III:** Reference points for measurements: **A-** Belly button, **B-** 10cm above belly button point, **C-** 10cm under belly button point

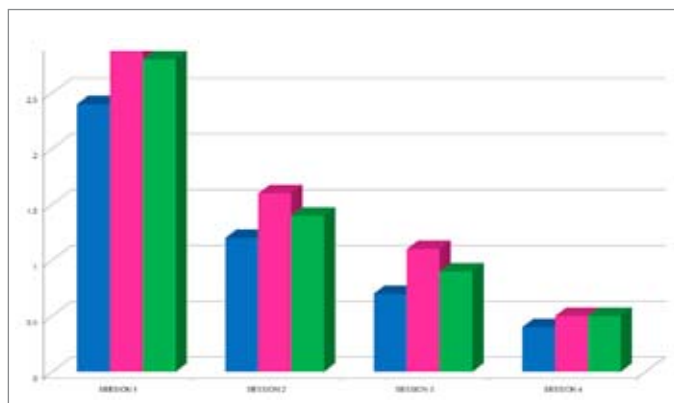
## Results and Conclusion

Photographs and circumference measurements were made at fixed reference points (upper, middle and lower abdomen) before the first treatment and 2 weeks after the final treatment. Improvement in body contouring was noticed on all subjects. Subjects reported minimal heat sensation during all treatment. No adverse effects were recorded during the treatment, afterwards, or during the follow up. After the last treatment subjects presented an average circumference reduction of 4.2cm (Figures 6 and 7). Another aspect noted was a reduction in average circumference after each session (Figure 5) and that the treatment can be used in different areas (Figure 8 and 9) with great results.

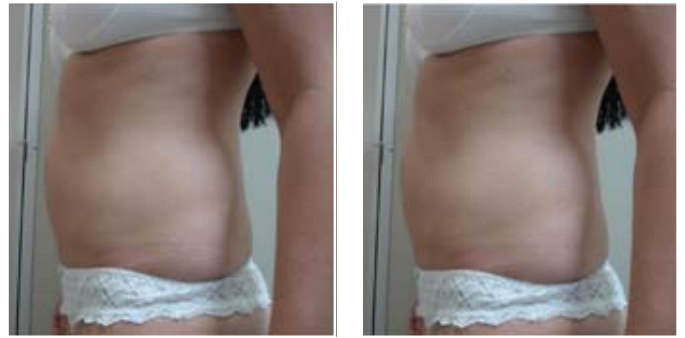**In the Brazilian experience the combination of ultrasound and radio frequency has proven to be safe and effective for the purpose of body contouring and with high subject satisfaction.**



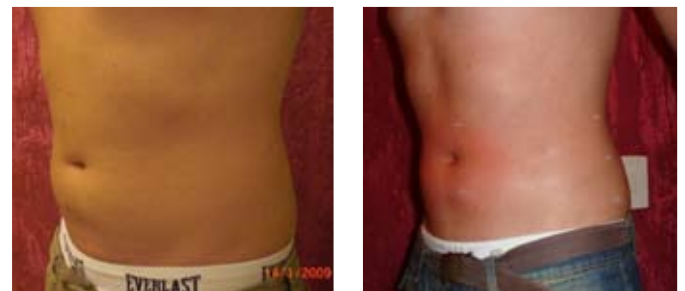**Figure 4:** Average circumference loss after 4 sessions



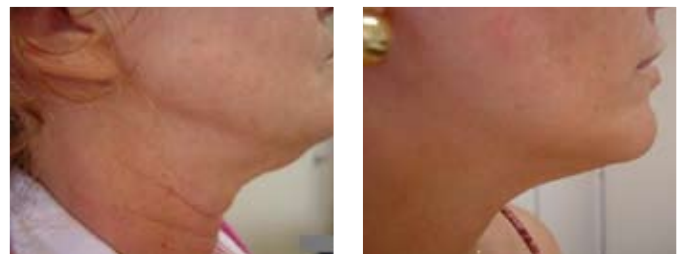
**Figure 5:** Average circumference loss after each session



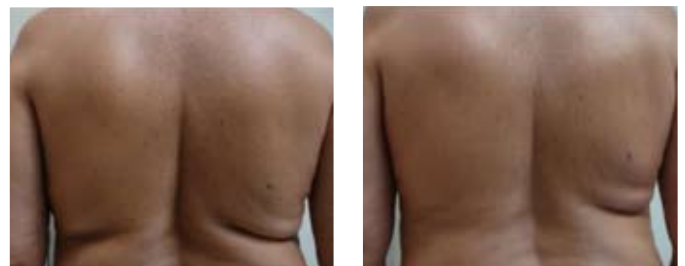**Figure 6:** Female - Age 33 - 4 Tx - 4.5cm reduction



**Figure 7:** Male - Age 28 - 4 Tx - 4.0cm reduction



**Figure 8:** Female - Age 45 - 4 Tx- new application area



**Figure 9:** Female - Age 32 - 4 Tx- new application area